



**PRESENTING CLINICAL SIGNS**

**DATE** History: Low-grade squeaky left apical murmur.

**5/9/23 ECHOCARDIOGRAPHIC FINDINGS**

2D, M-mode, and Doppler study.

**PERFORMED BY:** Left atrial size is normal. The mitral valve is normal. Left ventricular dimensions are normal. Left ventricular systolic function is hyperdynamic. The aorta and aortic valve appear normal, though there is very mildly increased flow velocity in the ascending aorta. Right atrial and right ventricular dimensions are normal. The tricuspid valve is normal. The pulmonary artery and pulmonic valve are normal. No shunting lesions are visualized. No pericardial effusion or cardiac masses are seen.

**INTERPRETED BY:** Keith Blass, DVM, MS, DACVIM (Cardiology)

**PATIENT** LA - 27.1 mm  
LVIDd - 24.0 mm  
LVIDs - 12.1 mm  
FS - 49.6%  
RA - 17.0 mm  
LVOT - 1.58 m/s  
RVOT - 1.02 m/s

Chico Reshma

**ASSESSMENT/RECOMMENDATIONS**

**SPECIES** Normal echocardiogram

**Canine** This examination demonstrates no evidence of structural heart disease. Chico's murmur appears to be due to the presence of very mildly increased flow velocity in his aorta, which is a common reason for a functional/innocent murmur to develop in dogs.

**BREED** No therapy is recommended based on this exam.

**Shih Tzu** A recheck echocardiogram is recommended if the characteristics of Chico's murmur change, or if other new physical exam and/or clinical abnormalities suggestive of cardiac dysfunction develop.

**SEX**

**MN**

**AGE**

4 y

**WEIGHT**

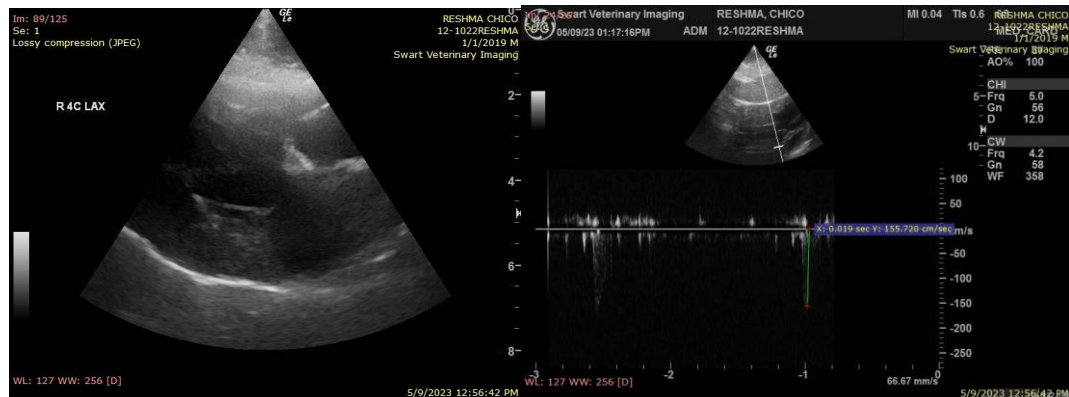
28 lb

**HOSPITAL NAME**

Swart Veterinary Imaging

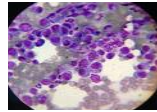
**REFERRING VET**

Dr. Swart



The information and recommendations provided are based on the images presented by the referring veterinarian. No evaluation can be communicated regarding pathology that was not visible in the image/video clips provided.

Thank you for this referral. If the clinical or image interpretation does not parallel your findings or



if I can be of any further assistance please contact me.

**DATE**

5/9/23

**Keith Blass, DVM, MS, DACVIM (Cardiology)**  
KeithBlass@gmail.com  
631-804-5754

**PERFORMED BY:**

Dr. Meredith Swart

**INTERPRETED BY**

Keith Blass, DVM,  
MS, DACVIM  
(Cardiology)

**PATIENT**

Chico Reshma

**SPECIES**

Canine

**BREED**

Shih Tzu

**SEX**

MN

**AGE**

4 y

**WEIGHT**

28 lb

**HOSPITAL NAME**

Swart Veterinary  
Imaging

**REFERRING VET**

Dr. Swart